Swiss-Teleradiology (Swiss-TR) SA

Chemin des Colombaires 13, 1096 Cully · info@swiss-tr.ch

SAMPLE – fictitious case: patient, examination and findings are made up.

Report — second opinion

Patient	Max Muster
Date of birth	01.01.1970
Request	SAMPLE of 28.11.2026
Specialty	Pulmonology

Indication

Persistent cough for three months. Lung nodule reported on a first CT scan. Second opinion requested.

Technique

Chest CT without contrast, 1 mm thin slices.

Findings

5 mm solid nodule in the right upper lobe, with smooth margins, without calcification. No other nodule. No mediastinal lymphadenopathy. No pleural effusion.

Conclusion

5 mm solid lung nodule, benign-looking, with no sign of malignancy. Follow-up to be discussed with the general practitioner according to current guidelines.

Validated by Expert radiologist (sample) on 28.11.2026 at 10:30.

SAMPLE

Swiss-Teleradiology (Swiss-TR) SA

Chemin des Colombaires 13, 1096 Cully · info@swiss-tr.ch

SAMPLE – fictitious case: patient, examination and findings are made up.

Patient summary

This summary comes with the expert's report and explains it in plain words. The report remains the reference document; discuss it with your doctor.

Patient	Max Muster
Date of birth	01.01.1970
Request	SAMPLE of 28.11.2026

In short

The CT scan shows a small 5 mm spot in the right lung, called a nodule. Its shape is regular and nothing suggests it is serious. The rest of the lungs is normal. Your doctor will tell you whether a check-up is useful.

Your questions

Is this nodule dangerous?

Nothing on these images suggests cancer: the nodule is small, regular and shows no worrying sign. Such nodules are very common and usually harmless.

Do I need another CT scan?

A follow-up CT may be suggested depending on your age and risk factors, smoking in particular. Your doctor will decide with you whether and when it is useful.

Key images

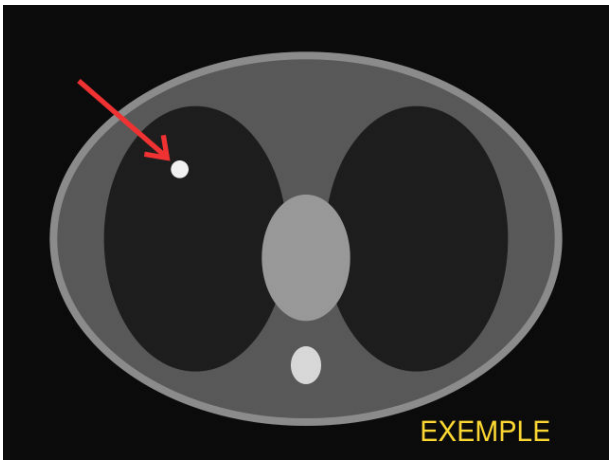

Axial slice (diagram): 5 mm nodule in the right upper lobe (arrow).

SAMPLE